Journal of Cardiology 83 (2024) 184–190

Contents lists available at ScienceDirect

Journal of Cardiology

journal homepage: www.elsevier.com/locate/jjcc

Original Article

Performance, safety, and biocompatibility of a novel PFO closure device in a long-term porcine model

Mateusz Kachel (MD, PhD) [a,b], Pedro Melo (MD) [a], Karl Van Wygerden (BS) [a], Yanping Cheng (MD) [a], Michael Corcoran (BS) [c], David S. Garlick (DVM) [d], Michelle Olson (MS) [d], Christopher D. Nielsen (MD) [e], Juan F. Granada (MD) [a], Grzegorz L. Kaluza (MD, PhD) [a,*]

[a] CRF Skirball Center for Innovation, Orangeburg, NY, USA
[b] American Heart of Poland, Center for Cardiovascular Research and Development, Katowice, Poland
[c] Encore Medical, Eagan, MN, USA
[d] StageBio, Frederick, MD, USA
[e] Medical University of South Carolina, Charleston, SC, USA

ARTICLE INFO

Article history:
Received 15 April 2023
Received in revised form 15 August 2023
Accepted 1 September 2023
Available online 7 September 2023

Keywords:
Cryptogenic stroke
Patent foramen ovale
Preclinical
Transcatheter occluder device

ABSTRACT

Background: As the catheter-based device closure of the patent foramen ovale (PFO) is expanding, novel devices aim to address the limitations of first-generation occluders (e.g. bulk, erosion, dislodgment). The second-generation device from Encore Medical (Eagan, MN, USA) features an articulating frame structure which allows the device to better conform to atrial anatomies, has lower disc thickness and metal mass/surface area, and is fully retrievable at any point in the procedure. The aim of the study was to evaluate the feasibility and safety of a novel low-profile, fully retrievable, Encore PFO closure device in the animal model.
Methods: Six swine underwent implantation of the novel PFO occluder under fluoroscopic and intra-cardiac echocardiography guidance and survived for 140 days. Interim transthoracic echocardiography (TTE) was conducted on Day 29. Following terminal angiography and TTE at 140 days, the hearts were subjected to gross and histopathologic analysis.
Results: All animals were successfully implanted and survived for 140 days. Interim TTE revealed proper device retention with no blood flow across the septum or thrombus in any of the animals. X-ray and pathology results showed preserved implant integrity with no fractures, and complete integration of the devices into the septum with complete re-endothelialization and nearly complete coverage by a mature, relatively thin neoendocardium. No surface fibrin deposition or thrombosis was reported.
Conclusions: In the standard porcine model, device retention and biocompatibility remained favorable following structural and functional device modifications exemplified by the second-generation PFO occluder from Encore Medical, including marked reduction of metal mass.
© 2023 Japanese College of Cardiology. Published by Elsevier Ltd. All rights reserved.

Introduction

Around 20–34 % of adults around the world are thought to have a patent foramen ovale (PFO) [1]. Although usually asymptomatic, PFO is increasingly recognized as an underlying cause of many cryptogenic strokes, amounting to one-third of all ischemic brain infarcts, exerting a significant burden on healthcare systems around the world [2,3]. Additionally, PFO can be associated with pathogenesis of different medical conditions, such as decompression illness, platypnea-orthodeoxia syndrome, and possibly with migraine with aura [4]. In the early 1990s a method of closing PFO using a double umbrella device was described [5]. Despite unequivocal results of the early studies, several randomized clinical trials and meta-analyses confirmed the superiority of PFO closure in comparison to medical therapy for the prevention of recurrent stroke [6–9]. Transcatheter intervention has become a gold-standard therapy for patients with cryptogenic stroke and a need for PFO closure [10–12]. The device-related adverse events, including thromboembolic events, post-procedural arrythmias and access site complications among others, remain relatively rare [13]. Nevertheless, given the young age of target population and thus a long life-expectancy, further optimization of the transseptal occluders is crucial. To that end, we present a preclinical study of a novel, low-profile, fully retrievable, PFO closure device that features an articulating frame structure and has lower disc thickness and metal mass.

* Corresponding author at: Skirball Center for Innovation, Cardiovascular Research Foundation, 8 Corporate Drive, Orangeburg, NY 10962, USA.
E-mail address: gkaluza@crf.org (G.L. Kaluza).

https://doi.org/10.1016/j.jjcc.2023.09.001
0914-5087/© 2023 Japanese College of Cardiology. Published by Elsevier Ltd. All rights reserved.

Materials and methods

Experimental design

The Good Laboratory Practice study was approved by the Institutional Animal Care and Use Committee and conducted in accordance with the Animal Welfare Act and the Guide for the Care and Use of Laboratory Animals (National Research Council, National Institutes of Health publication no. 85-23, revised 1996) at a U.S. Department of Agriculture-licensed, Association for the Assessment and Accreditation of Laboratory Animal Care International-accredited animal research facility. The study enrolled 6 Yucatan miniature swine weighing approximately 70 kg in which the Encore PFO Closure Device (Eagan, MN, USA) was implanted percutaneously under fluoroscopic and intra-cardiac echocardiography guidance. The animals were then followed up over 140 days, after which they were euthanized, their hearts harvested and submitted to histopathology analysis of the device integration in tissue, and to radiographic analysis of structural integrity.

Test device

The Encore PFO Closure Device is a percutaneous, transcatheter, PFO occluder. The device is constructed on a nitinol, titanium, and platinum-iridium frame. The frame of the device is covered on the right and left atrial sides with implantable polyester fabric which is attached to the frame with polypropylene sutures (Fig. 1). The design properties allow the device to be pulled into a delivery sheath and reshaped once it is released. Once the device is correctly positioned and firmly attached on both sides of the septum, it conforms to the septal wall due to the articulating nature of the device frame (Fig. 2). This is further highlighted by the fact that often PFO can have an elongated or channel-like form that hinders proper positioning. Additionally, due to its low metal mass/surface area, Encore PFO Closure Device is designed to facilitate subsequent transseptal puncture allowing for unrestricted access for structural interventions. The device is available in four sizes (20 mm/9F, 25 mm/10F, 30 mm/10F, 35 mm/11F); the specific size for each implantation was selected based on operator experience and anatomical size. The Encore PFO Closure Device examined in this study is an iteration of the previous version of the Ultrasept device (Cardia Inc., Eagan, MN, USA). The sails of the previous version of the Ultrasept were a type of polyvinyl alcohol (PVA) foam. This material required significant hydration prior to use to avoid damage to the sails during device loading and deployment. The Encore PFO Closure Device replaces the PVA sails with a proprietary implantable polyester fabric which mimics the elastic properties of the PVA, avoids potential damage from inadequate hydration, and increases the overall durability of the device.

Implantation procedure

After 10 days acclimation period, the animals were induced with an intramuscular anesthetic, placed in a supine position, intubated, and transitioned to isoflurane anesthesia and mechanical ventilation. After the proper depth of anesthesia was obtained, a femoral vein was accessed percutaneously, and an 11Fr sheath was placed to accommodate the Encore Delivery System. The contralateral femoral vein was accessed percutaneously, or a jugular vein accessed via cut-down, and a 9Fr sheath placed to accommodate intra-cardiac echocardiography (ICE). Baseline fluoroscopy and ICE were used to map the atrial chambers and atrial septum in order to select an appropriately sized occluder. A baseline activated clotting time (ACT) sample was taken followed by administration of a heparin bolus to achieve an ACT > 250 s prior to introduction of the device. Additional heparin boluses were administered as necessary to maintain appropriate anticoagulation throughout the duration of the procedure. Subsequently, a transseptal puncture was performed using a commercially available system and an extra stiff guidewire was directed into the left atrium/pulmonary vein. Following preparations in accordance with the instructions of use, the Encore PFO Closure Device was mounted on the dedicated delivery system, the trans-septal sheath was advanced, and the device was transferred to the interatrial septum region and implanted under ICE and fluoroscopy imaging. For the course of the study, beginning at Day −1, all animals were administered standard dual antiplatelet therapy consisting of 81 mg of aspirin (loading dose 325 mg) and 75 mg of clopidogrel (loading dose 150 mg) daily.

Post-procedural imaging

Interim imaging was obtained 29 days post-implantation in all animals. Imaging consisted of non-invasive transthoracic echocardiography



Fig. 1. Encore PFO closure device.



Fig. 2. Bench test pictures showing the stretchability of the Encore PFO closure device.

(TTE) for qualitative description of device placement (noting any dislodgment), degree of blood flow (0 = none, 1 = mild, 2 = moderate, 3 = severe), potential presence of thrombus, and any other abnormalities. At terminal time point (140 days) TTE and fluoroscopy were performed to evaluate the device. All imaging procedures utilized general anesthesia.

Statistical analysis

Continuous variables are expressed as means (standard deviation) while ordinal values (scores) are expressed as the values observed for each parameter. No further statistical comparisons were made within the group, and there was no control group used in this study.

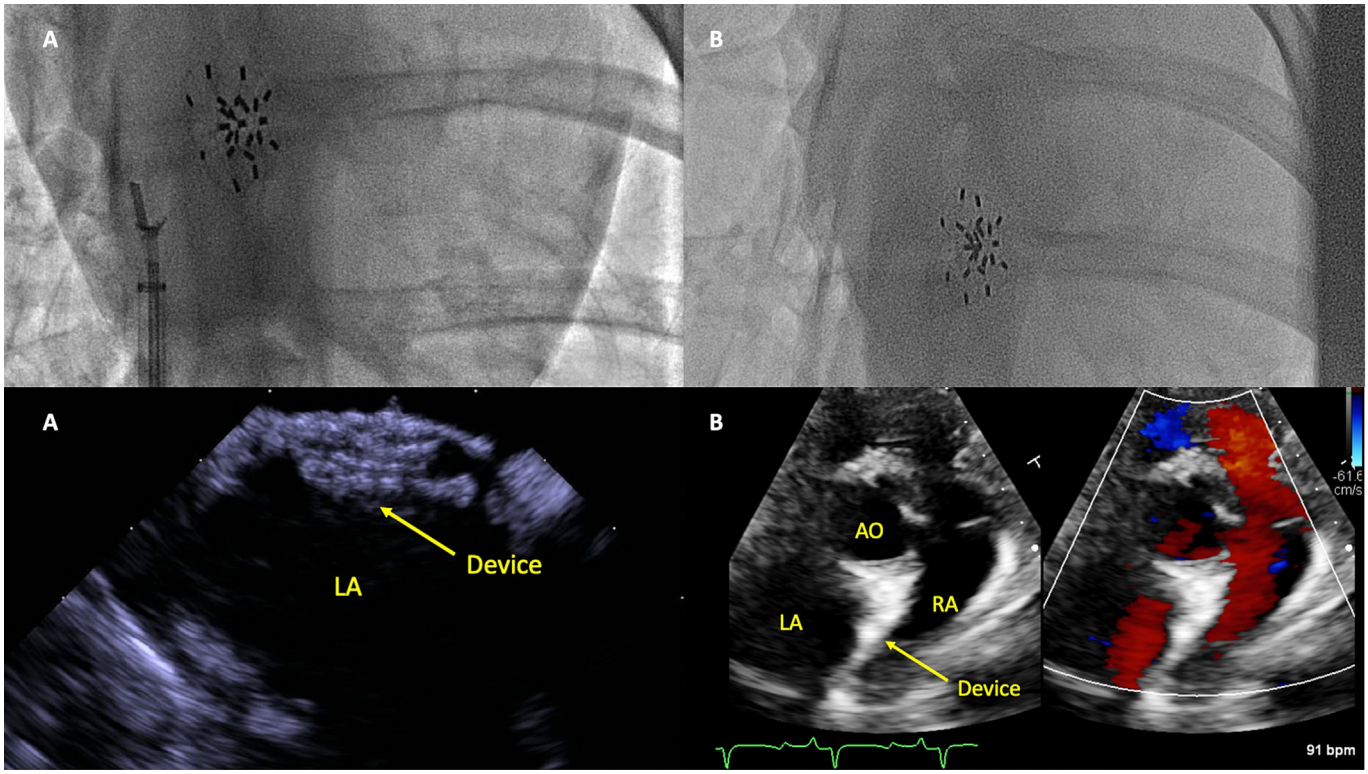

Fig. 3. Device position — representative echocardiography and fluoroscopy images. (A) Baseline; (B) 140-day follow-up.
AO, aorta; LA, left atrium; RA, right atrium.

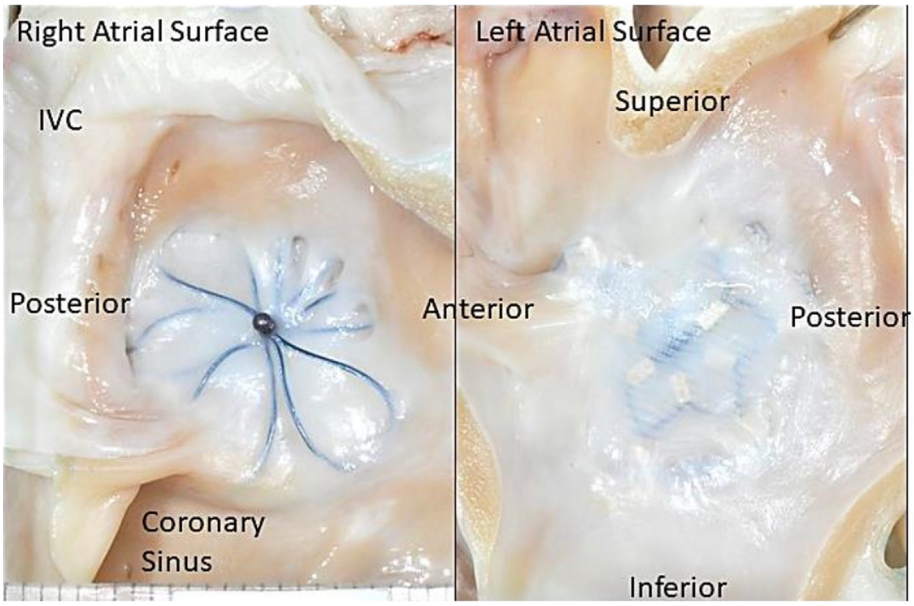

Fig. 4. Endocardial coverage of Encore PFO device — 140 days.
IVC, inferior vena cava.

Results

All animals were successfully implanted and survived the 140 days of follow-up. No adverse events, specifically device-related, were reported. Only the smallest size devices (20 mm/9F) were utilized for all animals. Both interim and terminal TTE showed no dislodgement of any of the implanted devices, nor any thrombus or any other abnormalities. The imaging reported no residual shunt in all animals. Same device positioning at follow-up, in comparison to initial position during implantation, was also confirmed in fluoroscopy in all cases. Fig. 3 shows the representative echocardiography and fluoroscopy images.

The necropsy examination showed no gross lesions, including none suggestive of downstream thromboembolism, ischemia, or infarction in examined organs/tissues (heart, lungs, kidney, rete mirabile, brain, right and left femoral veins, and caudal vena cava).

Histopathology analysis showed that almost the entirety of the surface of the devices on both left and right atrial sides were covered by a thin tissue (neoendocardium), with the exception of some portions of the loops of the nitinol frame and/or the center post on the right atrial sides (Fig. 4).

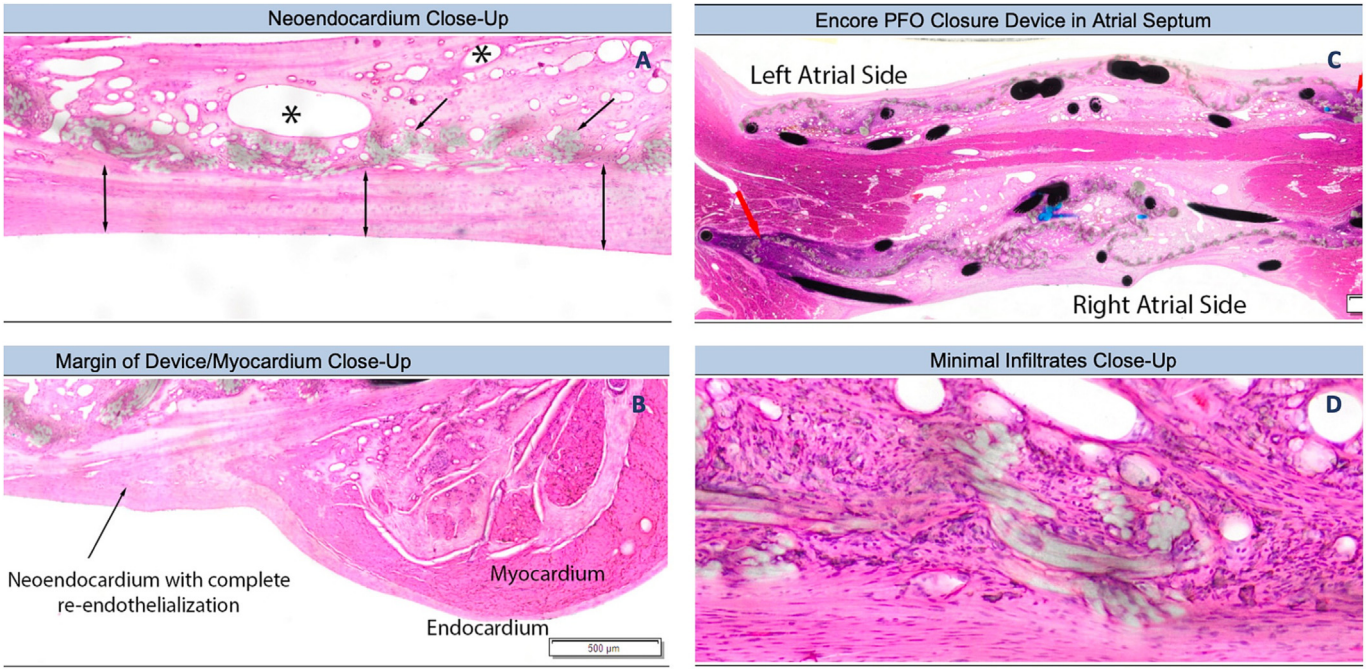

Fig. 5. Microscopic images of device healing and inflammatory response. (A) Interatrial septal wall, central section. Close up of polyester fabric (example at arrows) covered by mature neoendocardium along double-headed arrows. Polyester fabric integrated by granulation tissue with collagen deposition and new vascular channels (examples at asterisks). (B) Interatrial septal wall, central section. Close up at margin of pre-existent endocardium/myocardium and tissue response to Encore PFO closure device. Note seamless transition between neoendocardium over device and endocardium. (C) Interatrial septal wall, posterior section. Position of Encore PFO closure device in cross section of the atrial septum. Frame components are black and polypropylene sutures are blue. Focal moderate infiltrates of lymphocytes at red arrows in association with polyester fabric but is of limited distribution (<25 % along length of device). (D) Interatrial septal wall, central section. Grade 1 minimal inflammation of macrophage, lymphocyte, and giant cell infiltration associated with polyester fabric.

Via morphometric measurements, the average neointimal thickness for the left atrial side and the right atrial side of Encore PFO Closure devices within the interatrial septal wall was 239.9 μm and 293.4 μm, respectively. The average neointimal thickness over the device surfaces from measurements taken for all animals was 267.5 (45.5) μm. In almost all microscopic sections, there was a complete incorporation of the device at its margins with a smooth transition from the neoendocardium into the adjacent endocardium. This integration was composed of extensive granulation tissue. In most sections, the atrial septal defect created prior to deployment of the device was healed as noted by the presence of fibrosis with myocyte loss. There was no fibrin deposition or thrombus formation as part of the host tissue response on the surface of any of the Encore PFO Closure Devices. Cartilage metaplasia of limited intensity was sometimes seen in area of the connective tissue surrounding the device. Necrosis within the tissue around the devices was negligible and mineralization and ossification were not observed in association with any of the devices. Additionally, no evidence of injury to the interatrial myocardium, coronary sinus, or tricuspid/mitral valves was reported. Sectioning of the ventricular myocardium revealed no evidence of thromboembolization or ischemia.

The surface healing response was characterized by diffuse, relatively thin neointimal tissue (virtually complete coverage of the device) with fully mature neo- endocardial tissue with complete endothelialization. Inflammatory infiltrates associated with the Encore PFO Closure Device were predominated by Grade 1 (minimal/rare; 1–5 cells per high power field = hpf) to Grade 3 (moderate infiltrates) lymphocytes, Grade 1 to Grade 2 (mild; 6–10 cells/hpf) macrophages and giant cells, Grade 1 plasma cells with less frequent eosinophils (Grade 1 to Grade 2) (Fig. 5). Inflammatory cells were more frequently directed primarily against the polyester fabric portions of the device. Regarding the overall severity score for inflammation in response to the test article, almost all sections presented with minimal/mild intensity. Even in instances with more heavy lymphocyte infiltrates, the distribution of these infiltrates over the length of the device was invariably <50 %.

By radiographic, macroscopic, and microscopic evaluation, all devices were properly positioned in the atrial septum. The Encore PFO Closure Device implants showed no fractures or disconnections in any of the study animals (Fig. 6).

Discussion

The current study presented a comprehensive long-term evaluation of a novel PFO closure device in a preclinical model, proving its safety, feasibility of implantation, as well as effectiveness in closing a fenestration in the interatrial septum. All devices were successfully implanted, and animals survived until the termination. No adverse events were reported throughout the study, and no abnormal findings were observed in echocardiography imaging and histopathology. Because porcine atria are generally much smaller than those of a human of the same body weight, only the smallest size devices (20 mm/9F) were utilized in all animals.

Along with the rising number of interventions for PFO closure, the absolute number of early and late complications is also increasing, which is particularly significant given that the target population consists of young individuals with long life expectancy. According to randomized clinical trials, procedural complications have an incidence rate of 2.6 % [14], with the most frequent late complication being the device thrombosis seen in 1.0–2.0 % of cases on average [15]. As reported in a study that included 1000 PFO cases searching for thrombosis, these incidences occurred mainly on devices with an uncoated metal arm, ranging from 0 % to 7.1 % depending on the device type [16]. Post-procedurally, thrombus formation has been noted to occur at any phase after placement, ranging from 6 months to 8 years [17–19]. It is most commonly seen 4 weeks after device placement [20]. Most of these thrombi are detected on routine imaging and are usually asymptomatic. Nevertheless, clinically important thrombi may occur and can result in recurrent embolic events, neurological or peripheral. To prevent thrombus formation on exposed device elements, European associations propose 1–6 months of dual antiplatelet therapy (DAPT) after implantation [13]. This time should allow for a complete endothelialization of the device. In the present study, the devices were thoroughly evaluated for thrombus formation by means of transthoracic echocardiography at 29 and 140 days, as well as by histopathology. No signs of thrombus or embolization were found. Moreover, the examination of peripheral organs and tissues also reported no signs of pathology. Histopathology analysis demonstrated virtually complete coverage of the device with fully mature neoendocardium tissue and complete



Fig. 6. Radiography images — no device fractures or distortions visible.

endothelialization. These findings are in line with other studies that reported that the complete neoendothelialization process was achieved within three months after implantation [21–25]. An optimal safety profile of the test device is further highlighted by the fact that the experiment was conducted using porcine model. As reported in literature, swine are confirmed to be hypercoagulable as compared to humans [26].

Residual shunt after PFO closure constitutes a serious finding that is frequently observed in clinical practice (reported in up to 25 % of patients) and can lead to new thromboembolic complications [27–29]. In an analysis including a prospective cohort of 1078 patients who underwent PFO closure secondary to a cryptogenic stroke, a residual shunt was observed in 22.5 % of 243 patients [30]. Of these, 13.9 % were small shunts, and 8.6 % moderate to large. The primary outcome of the study was a composite score of transient ischemic attack (TIA) and stroke that occurred 2.32 times per 100 patient-years in the shunt group and 0.75 times per 100 patient-years in the no-shunt group with a risk of stroke or recurrent TIA (HR, 3.05; 95 % CI, 1.65–5.62; *p*-value, <0.001). The above emphasizes a need for new PFO devices that will be suited for different anatomical variations and improve the success rate of the procedure with minimizing complications and residual shunts rate. The Encore PFO occluder features an articulating frame structure which was conceived for the device to better conform to varying atrial and PFO anatomies (e.g. slit-like and tunnel or channel-like). Additionally, the device is fully retrievable and repositionable until released, enabling meticulous placement, and potentially minimizing leakage for better accommodation to challenging anatomies. The latter requires further confirmation in clinical setting. In-depth evaluation by means of TTE and fluoroscopy showed no residual shunt in any of the implanted devices both at interim and terminal follow-up. The latter was confirmed in histopathology which described an optimal device positioning and complete sealing of the fenestration.

The frame structure of the tested device is constructed from stranded nitinol wire. The design of the strand is intended to increase the fatigue life of the implant while decreasing pressure on adjacent tissue which is known to predispose to erosion. This concept aims to decrease the risk of fracture in comparison to larger diameter solid wires. Although rare, late wire fractures have been reported in Gore Cardioform occluder (Gore, Flagstaff, AZ, USA) whose frame is built from solid wire [31]. The Encore PFO Closure Device implants showed no fractures or disconnections in our preclinical study, although the long-term clinical data would be necessary in a significant patient population to prove such an advantage in the clinical setting.

Furthermore, the rapid increase in the number of structural procedures performed worldwide requires new solutions to be implemented that will facilitate easy and feasible transseptal access for future interventions. The currently available technologies often consist of dense nitinol mesh that can effectively challenge septal puncture post-implantation. The Encore PFO closure device is characterized by a unique multi-element frame design with low metal mass/surface area that will likely enable the preservation of transcatheter access to the left atrium post-implantation. However, this theoretical advantage is yet to be confirmed.

Limitations

The present study includes a few limitations that need to be acknowledged. Firstly, the PFO was artificially created using a septal puncture device. This technique creates fenestrations that are similar in shape and size, not reflecting the wide anatomical variety as expressed in clinical scenarios, especially challenging cases. Secondly, the study was not directed towards investigating potential arrhythmias after device placement (specifically atrial fibrillation — AF). However, based on the electrocardiograms from implantation, interim control, and terminal procedure, we observed no such episodes. Moreover, the tested device is the next iteration of Cardia Ultrasept PFO occluder, which was reported in the literature to have a lower incidence rate of post-implantation AF than the competitors [32]. Finally, the fact that all devices were tight at animal death regarding transseptal blood flow does hardly suffice to project a high clinical complete closure rate in humans. In humans, the tightness of a PFO device is assessed regarding right-to-left shunt at the end of a sustained Valsalva maneuver, which was not performed in this animal study.

Conclusions

The present study confirmed a good feasibility and safety profile of a novel percutaneous PFO closure device at 140 days' follow-up. In the standard porcine model, device retention and biocompatibility remained favorable following structural and functional device modifications exemplified by Encore Medical's second-generation PFO occluder, including marked reduction of metal mass.

Funding

Skirball Center for Innovation received institutional funding from Encore Medical to conduct this preclinical study.

Declaration of competing interest

Michael Corcoran is an employee of, and Dr. Nielsen is a consultant to Encore Medical.

References

[1] Calvert PA, Rana BS, Kydd AC, Shapiro LM. Patent foramen ovale: anatomy, outcomes, and closure. Nat Rev Cardiol 2011;8:148–60. https://doi.org/10.1038/nrcardio.2010.224.
[2] Li L, Yiin GS, Geraghty OC, Schulz UG, Kuker W, Mehta Z, et al. Incidence, outcome, risk factors, and long-term prognosis of cryptogenic transient ischaemic attack and ischaemic stroke: a population-based study. Lancet Neurol 2015;14:903–13. https://doi.org/10.1016/S1474-4422(15)00132-5.
[3] Meier B, Jüni P. Patent foramen ovale and cryptogenic stroke. N Engl J Med 2013;369:91. https://doi.org/10.1056/NEJMc1305429.
[4] Giblett JP, Williams LK, Kyranis S, Shapiro LM, Calvert PA. Patent foramen ovale closure: state of the art. Interv Cardiol 2020;15:e15. https://doi.org/10.15420/icr.2019.27.
[5] Bridges ND, Hellenbrand W, Latson L, Filiano J, Newburger JW, Lock JE. Transcatheter closure of patent foramen ovale after presumed paradoxical embolism. Circulation 1992;86:1902–8. https://doi.org/10.1161/01.cir.86.6.1902.
[6] Carroll JD, Saver JL, Thaler DE, Smalling RW, Berry S, MacDonald LA, et al. Closure of patent foramen ovale versus medical therapy after cryptogenic stroke. N Engl J Med 2013;368:1092–100. https://doi.org/10.1056/NEJMoa1301440.
[7] Saver JL, Carroll JD, Thaler DE, Smalling RW, MacDonald LA, Marks DS, et al. Long-term outcomes of patent foramen ovale closure or medical therapy after stroke. N Engl J Med 2017;377:1022–32. https://doi.org/10.1056/NEJMoa1610057.
[8] Søndergaard L, Kasner SE, Rhodes JF, Andersen G, Iversen HK, Nielsen-Kudsk JE, et al. Patent foramen ovale closure or antiplatelet therapy for cryptogenic stroke. N Engl J Med 2017;377:1033–42. https://doi.org/10.1056/NEJMoa1707404.
[9] Lee PH, Song JK, Kim JS, Heo R, Lee S, Kim DH, et al. Cryptogenic stroke and high-risk patent foramen ovale: the DEFENSE-PFO trial. J Am Coll Cardiol 2018;71:2335–42. https://doi.org/10.1016/j.jacc.2018.02.046.
[10] Wein T, Lindsay MP, Côté R, Foley N, Berlingieri J, Bhogal S, et al. Canadian stroke best practice recommendations: secondary prevention of stroke, sixth edition practice guidelines, update 2017. Int J Stroke 2018;13:420–43. https://doi.org/10.1177/1747493017743062.
[11] Kuijpers T, Spencer FA, Siemieniuk RAC, Vandvik PO, Otto CM, Lytvyn L, et al. Patent foramen ovale closure, antiplatelet therapy or anticoagulation therapy alone for management of cryptogenic stroke? A clinical practice guideline. BMJ 2018;362:k2515. https://doi.org/10.1136/bmj.k2515.
[12] Pristipino C, Filice FB. Long-term benefits and risks in patients after persistent foramen ovale closure: a contemporary approach to guide clinical decision making. Kardiol Pol 2021;79:248–54. https://doi.org/10.33963/KP.15817.
[13] Pristipino C, Sievert H, D'Ascenzo F, Louis Mas J, Meier B, Scacciatella P, et al. European position paper on the management of patients with patent foramen ovale. General approach and left circulation thromboembolism. Eur Heart J 2019;40:3182–95. https://doi.org/10.1093/eurheartj/ehy649.
[14] Turc G, Calvet D, Guérin P, Sroussi M, Chatellier G, Mas JL, et al. Closure, anticoagulation, or antiplatelet therapy for cryptogenic stroke with patent foramen ovale: systematic review of randomized trials, sequential meta-analysis, and new insights from the CLOSE study. J Am Heart Assoc 2018;7:e008356. https://doi.org/10.1161/JAHA.117.008356.
[15] Abaci A, Unlu S, Alsancak Y, Kaya U, Sezenoz B. Short and long term complications of device closure of atrial septal defect and patent foramen ovale: meta-analysis of 28,142 patients from 203 studies. Catheter Cardiovasc Interv 2013;82:1123–38. https://doi.org/10.1002/ccd.24875.

[16] Krumsdorf U, Ostermayer S, Billinger K, et al. Incidence and clinical course of thrombus formation on atrial septal defect and patient foramen ovale closure devices in 1,000 consecutive patients. J Am Coll Cardiol 2004;43:302–9. https://doi.org/10.1016/j.jacc.2003.10.030.
[17] Uysal F, Bostan ÖM, Şenkaya Sığnak I, Güneş M, Çil E. Huge thrombus formation 1 year after percutaneous closure of an atrial septal defect with an Amplatzer septal occluder. Anatol J Cardiol 2016;16:63–4. https://doi.org/10.14744/AnatolJCardiol.2015.6538.
[18] Canpolat U, Gürses KM, Sunman H, Kaya EB, Aytemir K, Oto A. Embolic stroke due to left atrial thrombus 2 years after PFO closure. Herz 2014;39:161–2. https://doi.org/10.1007/s00059-013-3783-5.
[19] Ruge H, Wildhirt SM, Libera P, Vogt M, Holper K, Lange R. Images in cardiovascular medicine. Left atrial thrombus on atrial septal defect closure device as a source of cerebral emboli 3 years after implantation. Circulation 2005;112:e130–1. https://doi.org/10.1161/CIRCULATIONAHA.104.492017.
[20] Kovacevic P, Srdanovic I, Ivanovic V, Rajic J, Petrovic N, Velicki L. Late complications of transcatheter atrial septal defect closure requiring urgent surgery. Postepy Kardiol Interwencyjnej 2017;13:335–8. https://doi.org/10.5114/aic.2017.71617.
[21] Foth R, Quentin T, Michel-Behnke I, Vogt M, Kriebel T, Kreischer A, et al. Immunohistochemical characterization of neotissues and tissue reactions to septal defect-occlusion devices. Circ Cardiovasc Interv 2009;2:90–6. https://doi.org/10.1161/CIRCINTERVENTIONS.108.810507.
[22] Zhang C, Huang Y, Bertog S, Huang T, Huang W, Huang X, et al. Experimental study of the SpiderTM patent foramen ovale occluder. Cerebrovasc Dis 2011;32:51–6. https://doi.org/10.1159/000326078.
[23] Sigler M, Jux C. Biocompatibility of septal defect closure devices. Heart 2007;93:444–9. https://doi.org/10.1136/hrt.2006.098103.
[24] Bloch Thomsen A, Schneider M, Baandrup U, Stenbøg EV, Hasenkam JM, Bagger JP, et al. Animal experimental implantation of an atrial septal defect occluder system. Heart 1998;80:606–11. https://doi.org/10.1136/hrt.80.6.606.
[25] Krizanic F, Sigler M, Figulla HR. Transvenous closure of patent foramen ovale: preliminary results with a new self-expanding nitinol wire mesh in a Swine model. Cardiol Res Pract 2009;2009:943453. https://doi.org/10.4061/2009/943453.
[26] Sondeen JL, de Guzman R, Amy Polykratis I, Dale Prince M, Hernandez O, Cap AP, et al. Comparison between human and porcine thromboelastograph parameters in response to ex-vivo changes to platelets, plasma, and red blood cells. Blood Coagul Fibrinolysis 2013;24:818–29. https://doi.org/10.1097/MBC.0b013e3283646600.
[27] Mas JL, Derumeaux G, Guillon B, Massardier E, Hosseini H, Mechtouff L, et al. Patent foramen ovale closure or anticoagulation vs. antiplatelets after stroke. N Engl J Med 2017;377:1011–21. https://doi.org/10.1056/NEJMoa1705915.
[28] Søndergaard L, Kasner SE, Rhodes JF, Andersen G, Iversen HK, Nielsen-Kudsk JE, et al. Patent foramen ovale closure or antiplatelet therapy for cryptogenic stroke. N Engl J Med 2017;377:1033–42. https://doi.org/10.1056/NEJMoa1707404.
[29] Windecker S, Wahl A, Nedeltchev K, Arnold M, Schwerzmann M, Seiler C, et al. Comparison of medical treatment with percutaneous closure of patent foramen ovale in patients with cryptogenic stroke. J Am Coll Cardiol 2004;44:750–8. https://doi.org/10.1016/j.jacc.2004.05.044.
[30] Deng W, Yin S, McMullin D, Inglessis-Azuaje I, Elmariah S, Hung J, et al. Residual shunt after patent foramen ovale closure and long-term stroke recurrence: a prospective cohort study. Ann Intern Med 2020;172:717–25. https://doi.org/10.7326/M19-3583.
[31] Gillespie MJ, Javois AJ, Moore P, Forbes T, Paolillo JA, GSO Investigator Group. Use of the GORE® CARDIOFORM septal Occluder for percutaneous closure of secundum atrial septal defects: results of the multicenter U.S. IDE trial. Catheter Cardiovasc Interv 2020;95:1296–304. https://doi.org/10.1002/ccd.28814.
[32] Nachoski D, Schroeder J, Almalla M, Kubini R, Tchaikovski V, Kosinski C, et al. Dual-center experiences with interventional closure of patent foramen ovale: a medium-term follow-up study comparing two patient groups aged under and over 60 years. Clin Cardiol 2021;44:386–91. https://doi.org/10.1002/clc.23548.